Injury Extra (2008) **39**, 291—295

available at www.sciencedirect.com

ScienceDirect

journal homepage: www.elsevier.com/locate/inext

CASE REPORT

Unusual fracture combination with Charcot arthropathy and juvenile-onset diabetes

Melih Güven [a,*], Namık Kemal Özkan [a], Volkan Kılınçoğlu [b], Budak Akman [a], Abdülkadir Dost [a]

[a] *Göztepe Training and Research Hospital, 2nd Orthopaedic and Traumatology Clinic, Göztepe, Istanbul, Turkey*
[b] *Fatih Sultan Mehmet Training and Research Hospital, Orthopaedic and Traumatology Clinic, Istanbul, Turkey*

Accepted 6 March 2008

Introduction

Charcot arthropathy is a non-infective, destructive process activated by cumulative mechanical trauma that leads to bone and joint destruction[1,11]; peripheral neuropathy secondary to diabetes mellitus is the most common cause.[7] There are several reports in the literature that indicate the high risk of fracture in such cases, particularly when associated with juvenile-onset type 1 diabetes mellitus.[2,8,10,11] Diabetes-related Charcot arthropathy primarily affects the foot and ankle, most frequently the tarsometatarsal, transverse tarsal and subtalar joints.[1,7] It has been shown that delay in diagnosis and treatment of fracture may cause severe deformity among adults with juvenile-onset diabetes mellitus.[10]

We present the case of a woman with juvenile-onset diabetes mellitus, who had a satisfactory clinical outcome after conservative treatment for avulsion fracture of the calcaneus and contralateral tarsometatarsal and distal metatarsal fractures, where diagnosis was delayed.

Case report

A 27-year-old woman with a long-standing history of diabetes mellitus was referred to our hospital with left ankle sprain, complaining of painless swelling of the left foot. She had first received the diagnosis of diabetes mellitus 22 years previously, and had been dependent on insulin since then. Physical examination revealed prominent swelling on the lateral border of the left foot without pain, warmth and erythema. Neurological examination showed bilateral sensory neuropathy which was confirmed by electromyography. Plain radiographs demonstrated an oblique fracture of the fifth metatarsal (Fig. 1a). A below-knee cast was applied and weight bearing was not allowed for 3 weeks. By the end of the 3rd week, the woman had a sprain of the right ankle and complained of swelling of the right ankle and heel. Plain radiographs showed an avulsion fracture of the right calcaneus (Fig. 1b). A below-knee cast was applied to the right foot and the cast on the left foot was removed, allowing weight bearing on the left leg with orthosis. After a further 6 weeks, the cast on the right foot was removed and bilateral weight bearing was initiated without any protective orthosis.

The woman was referred to our hospital again with swelling of the left foot, 6 months after the first referral. There had been no history of trauma. Plain radiographs showed proximal fractures of the first and second metatarsals and distal fractures of the second, third and fourth metatarsals with callus formation (Fig. 2). She had no pain and did not complain of the deformities. The condition was treated with supportive bandaging only and weight bearing was allowed.

After a total of 18 months of follow-up, the woman had no complaints about either foot. Plain radiographs showed complete healing of the metatarsal fractures with minimally angular deformities of the third and fourth metatarsals of

* Corresponding author. Tel.: +90 216 566 40 00x1282; fax: +90 2165663636.
E-mail address: maguven2000@gmail.com (M. Güven).

1572-3461/$ — see front matter
doi:10.1016/j.injury.2008.03.004

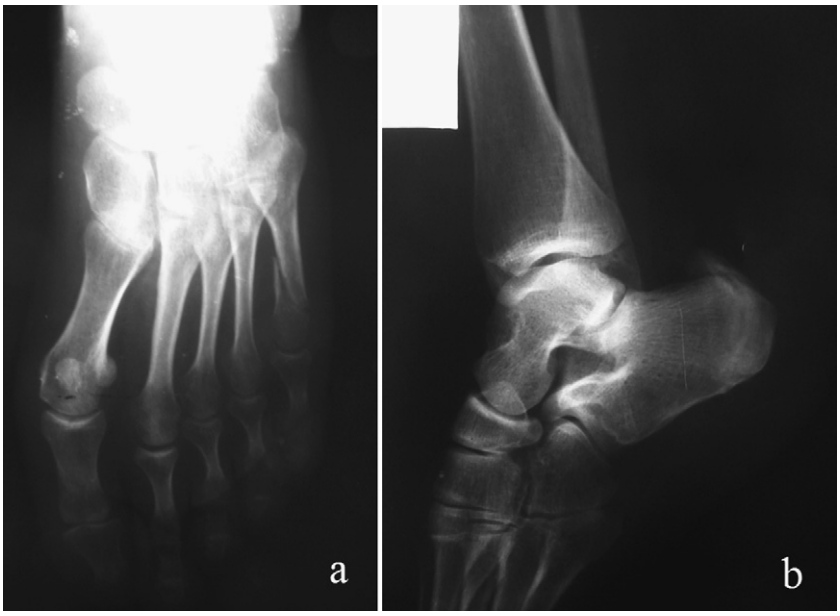

Figure 1 (a) Fracture of the fifth metatarsal of the left foot and (b) avulsion fracture of the calcaneus of the right foot.

the left foot (Fig. 3). There was further displacement and non-union of the calcaneal avulsion fracture of the right foot (Fig. 4). However, the active ranges of motion of the right and left ankles were, respectively, dorsiflexion 15° and 20° and plantar flexion 25° and 30°. The woman could walk independently without pain or restriction (Fig. 5).

Discussion

The lower extremities of people with a long-standing history of diabetes mellitus may have been exposed to more trauma than those of normal individuals, because of associated sensory neuropathy. Early recognition and treatment of inju-

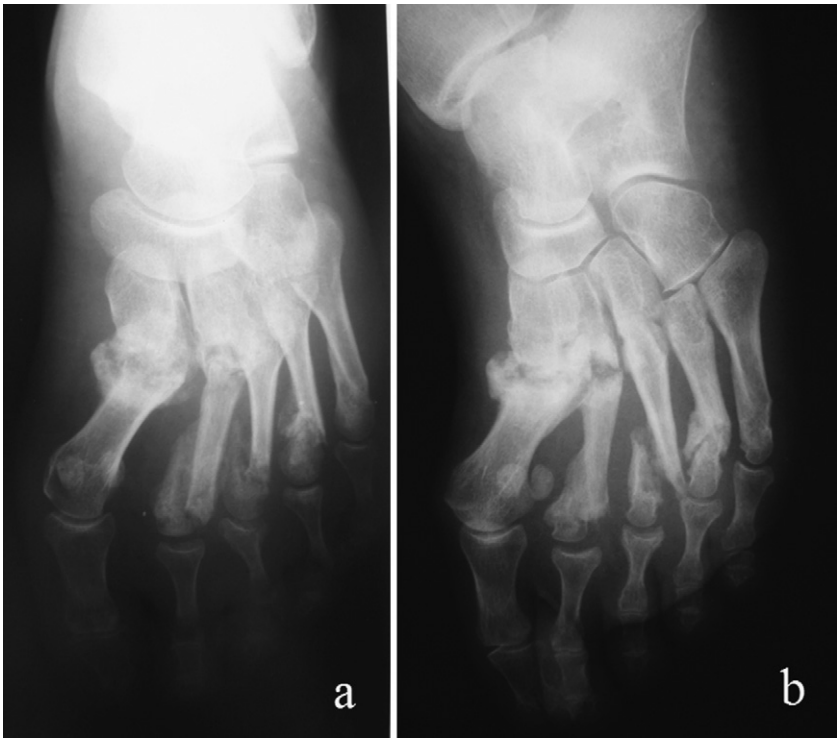

Figure 2 Charcot arthropathy characterised by proximal fractures of the first and second metatarsals and distal fractures of the second, third and fourth metatarsals with callus formation: (a) anteroposterior radiograph at the time of the diagnosis and (b) oblique radiograph 3 months later.

Figure 3 Radiographs at the end of the 18-month follow-up: (a) anteroposterior radiograph of both feet and (b) oblique radiograph of the left foot.

ries of people with diabetes are important in the prevention of Charcot arthropathy.[11] A history of trauma which may be apparently minor, such as sprain, twist or stress fracture, is present in 22–53% of cases of Charcot arthropathy.[8,9,11] Unfortunately the diagnosis of such fractures is often delayed because sensory neuropathy may eliminate the sensation of pain.

Brodsky[1] described a classification system based on the anatomical location of the destruction. This system is commonly used to classify neuropathic deformities of the foot. A type 1 event involves all or portions of the tarsometatarsal (Lisfranc) joints, the most common location for neuroarthropathy of the foot. Injury of the transverse tarsal (Chopart), subtalar or all three joints of the hindfoot is classified as a type 2 event. Types 3A and 3B comprise damage to the ankle and calcaneal tuberosity, respectively. Type 4 includes trauma to more than one anatomical region, either concurrently or sequentially, complicating treatment and prognosis.[11] Type 5 Charcot arthropathy expresses arthropathy involving the forefoot; types 3B and 5 are uncommon in orthopaedic practice.

Bilateral involvement has been reported in 9–30% of fractures associated with neuropathic arthropathy.[1–3] Of adults with juvenile-onset diabetes mellitus and neuropathic arthropathy, 58% may have fractures in more than one anatomical region, 72% of which develop contralateral frac-

Figure 4 Lateral radiograph of the right foot and ankle at the end of the 18-month follow-up.

mity with a protective cast or orthosis during treatment of an acute neuropathic fracture. We applied in the present case a protective orthosis for the left foot, and treated conservatively the avulsion fracture of the calcaneus on the right foot using a below-knee cast. However, 6 months later an unusual pattern of Charcot foot developed in the left lower extremity.

Timely diagnosis and treatment of fractures among people with juvenile-onset diabetes mellitus can help prevent the deformities associated with later stages, and therefore physicians should cultivate a high index of suspicion in the diagnosis of these lesions.[11] The treatment protocol in our case was no different from that described in the literature, but the diagnosis of multiple metatarsal fractures was delayed. However, all metatarsal fractures healed without significant residual morbidity in spite of the

Figure 5 (a) Clinical appearance of both feet and (b) ability to rise on both forefeet.

tures.[2] To our knowledge, there is in the English literature no previous case report describing the results of ipsilateral tarsometatarsal and distal metatarsal fractures (type 4) with contralateral calcaneal avulsion fracture (type 3B) treated conservatively in the context of juvenile-onset diabetes mellitus.

Since the first description of Charcot arthropathy, postponement of weight bearing has been key in the initial treatment of the acute Charcot foot. Pinzur[6] reported that at least half of cases with Charcot foot arthropathy could be treated successfully with a total-contact cast. Calcaneal posterior tuberosity avulsion fractures among people with diabetes have been adequately managed with non-operative treatment.[11] Surgery has been reserved for infection, unresolved skin ulceration or severe foot deformity.[4,5,9]

Clohisy and Thompson[2] reported their treatment results among 18 adults with juvenile-onset diabetes; 36% of those who attempted early weight bearing were not able to walk after completion of treatment and 27% had undergone amputation. Contralateral fracture developed among 8 (82%) of 11 individuals whose treatment involved weight bearing. Therefore these workers recommended prophylactic immobilisation of the uninvolved contralateral extre-

non-union of the avulsion fracture of the calcaneus. We suggest that the bone remodelling process may improve the deformities which develop secondary to the fractures, particularly among young persons with juvenile-onset diabetes mellitus.

References

1. Brodsky JW. The diabetic foot. In: Coughlin MJ, Mann RA, editors. Surgery of the foot and ankle. St Louis, MO: Mosby; 1999. p. 895—969.
2. Clohisy DR, Thompson RC. Fractures associated with neuropathic arthropathy in adults who have juvenile-onset diabetes. J Bone Joint Surg Am 1988;70:1192—200.
3. Clouse ME, Gramm HF, Legg M, Flood T. Diabetic osteoarthropathy: clinical and roentgenographic observations in 90 cases. Am J Roentgenol 1974;121:22—34.
4. Johnson JE. Operative treatment of neuropathic arthropathy of the foot and ankle. J Bone Joint Surg Am 1998;80:1700—9.
5. Lesko P, Maurer RC. Talonavicular dislocations and midfoot arthropathy in neuropathic diabetic feet. Clin Orthop 1989;240:226—31.
6. Pinzur MS. Surgical versus accommodative treatment for Charcot arthropathy of the midfoot. Foot Ankle Int 2004;25:545—9.

7. Pinzur MS. Current concepts review: Charcot arthropathy of the foot and ankle. Foot Ankle Int 2007;28:952—9.
8. Pinzur MS, Sage R, Stuck R, Kaminsky S, Zmuda A. A treatment algorithm for neuropathic (Charcot) midfoot deformity. Foot Ankle Int 1993;14:189—97.
9. Schon LC, Easley ME, Weinfeld SB. Charcot neuroarthropathy of the foot and ankle. Clin Orthop 1998;349:116—31.
10. Thompson RC, Clohisy DR. Deformity following fracture in diabetic neuropathic osteoarthropathy: operative management of adults who have type-I diabetes. J Bone Joint Surg Am 1993;75: 1765—73.
11. Trepman E, Nihal A, Pinzur MS. Current topics review: Charcot neuroarthropathy of the foot and ankle. Foot Ankle Int 2005;26: 46—63.