Arch Orthop Trauma Surg (2010) 130:1201–1207
DOI 10.1007/s00402-009-0986-6

ORTHOPAEDIC SURGERY

Transosseous capsuloplasty improves the outcomes of Lindgren–Turan distal metatarsal osteotomy in moderate to severe hallux valgus deformity

Namık Kemal Özkan · Melih Güven · Budak Akman · Murat Çakar · Adnan Konal · Yalçın Turhan

Received: 7 July 2009 / Published online: 15 October 2009

Abstract
Introduction Lindgren–Turan osteotomy used in hallux valgus deformity is a subcapital, transverse displacement osteotomy of the first metatarsal without any additional capsular repair. The aims of this study are to describe a transosseous capsuloplasty technique in this procedure and evaluate whether capsuloplasty would improve the clinical and radiological outcomes in patients with moderate to severe hallux valgus deformity.
Methods Twenty-three feet operated by Lindgren–Turan osteotomy (Group B) and 25 feet operated by the same osteotomy combined with transosseous capsuloplasty (Group A) were evaluated retrospectively for the correction of the hallux valgus, intermetatarsal and distal metatarsal articular angles, sesamoid reduction, American Orthopaedic Foot and Ankle Society (AOFAS) Clinical Rating Scale as well as patient satisfaction. The mean postoperative follow-up was 14 (range 12–28) months.
Results All radiological parameters improved considerably as a result of both groups. However, postoperative improvements in intermetatarsal and distal metatarsal articular angles were greater in Group A. Complete reduction of medial sesamoid was achieved in 52% of patients in Group A, whereas 17.4% of patients in Group B had complete reduction. AOFAS scores and number of patients with complete satisfaction in Group A were significantly greater than that in Group B.
Conclusion Better clinical and radiological outcomes can be achieved in patients with moderate to severe hallux valgus deformity operated by Lindgren–Turan distal metatarsal osteotomy, when it combines with transosseous capsuloplasty.

Keywords Hallux valgus · Lindgren–Turan osteotomy · Transosseous capsuloplasty · Clinical outcome · Radiological outcome

N. K. Özkan · Y. Turhan
Orthopaedics and Traumatology Clinic,
Göztepe Training and Research Hospital,
Göztepe, Istanbul, Turkey

M. Güven (✉)
Department of Orthopaedics and Traumatology,
The Hospital of University of Abant Izzet Baysal, Bolu, Turkey
e-mail: maguven2000@gmail.com

B. Akman
Department of Orthopaedics and Traumatology,
Gülhane Military Medical Faculty Hospital, Istanbul, Turkey

M. Çakar
Orthopaedics and Traumatology Clinic,
Bağcılar Training and Research Hospital, Istanbul, Turkey

A. Konal
Orthopaedics and Traumatology Clinic,
Kartal Yavuz Selim Hospital, Istanbul, Turkey

Introduction

Hallux valgus is the most common deformity of the first metatarsal in adults [14]. A lot of surgical techniques including distal soft tissue procedures, distal or proximal metatarsal osteotomies, arthroplasties and combination procedures have been described for the correction of this deformity [2, 3]. Although the choice of appropriate surgical procedure still remains controversial, there is a general agreement that mild hallux valgus deformities can be successfully corrected by distal osteotomies, while preferred treatment option for moderate and severe deformities is a

distal soft tissue reconstruction combined with an osteotomy of the proximal end of the first metatarsal [2, 3, 15].

Distal metatarsal osteotomies may result in recurrent deformity, when they are used for the treatment of moderate and severe hallux valgus deformities [2, 3, 14, 17]. There are many publications [1, 3, 9, 13, 16, 17] in the literature describing the distal procedures; however, there is little documentation concerning the capsuloplasty and its importance in obtaining and maintaining the surgical correction.

Lindgren–Turan osteotomy is a subcapital, transverse displacement osteotomy of the distal part of the first metatarsal without any additional capsular repair procedure [13]. It was stated that this osteotomy should be preferred for the surgical treatment of patients with mild to moderate hallux valgus deformities due to the rate of undercorrection up to 30% [4, 17]. The aims of the presented study were to describe a transosseous capsuloplasty technique in Lindgren–Turan osteotomy and evaluate whether capsuloplasty would improve the clinical and radiological outcomes in patients with moderate to severe hallux valgus deformity.

Materials and methods

Patient population

The patient database was search for the time period September 2006 to May 2008 for patients who had undergone Lindgren–Turan osteotomy for hallux valgus deformity. The inclusion criteria for patients were an age of 17 years or older, pain unresponsive to shoewear modification and no radiographic evidence of degenerative arthritis of the first metatarsophalangeal joint. The exclusion criteria were a history of diabetes mellitus, previous operation of the affected foot, peripheral vascular disease, peripheral neuropathy, rheumatoid arthritis or other inflammatory diseases and inadequate documentation. According to these criteria, 42 patients (55 feet) were reviewed. Five patients (7 feet) could not be located. Thus, the study group consisted of 48 (11 bilateral) feet of 37 (36 females, 1 male) patients. The average age of the patients at the time of surgery was 47 years (range 24–69). The patients were divided in two groups taking into account whether the osteotomy combined with transosseous capsuloplasty (Group A) or not (Group B). All patients signed an informed consent form that had been approved by the institution's human subjects review board.

Clinical assessment

The American Orthopaedic Foot and Ankle Society (AOFAS) hallux-metatarsophalangeal-interphalangeal scale score [10] was used for the clinical preoperative and final follow-up evaluation. All patients were examined preoperatively by the first two authors who performed all operations. Follow-up evaluation was done by the third and fourth authors who did not involve in the primary treatment. In addition, patients also were questioned about the rate of their feet for overall satisfaction and cosmesis. For both outcome measures, patients stated they were "satisfied", "satisfied with reservation" or "not satisfied".

Radiological evaluation

Weightbearing anteroposterior and lateral radiographs of the entire foot preoperatively, immediate postoperatively and at the latest follow-up were used for the radiographical examination. The third author, who did not perform surgery, measured the angles. The hallux valgus angle (HVA), intermetatarsal angle (IMA) and distal metatarsal articular angle (DMAA) were measured according to the recommendations of AOFAS [18]. The position of the medial sesamoid relative to the midline axis of the first metatarsal was evaluated for sesamoid luxation (Grade 0: no displacement of sesamoid relative to the midline axis of the first metatarsal; Grade 1: overlap of <50% of sesamoid to the midline; Grade 2: overlap of greater than 50% of sesamoid to the midline; Grade 3: complete displacement of sesamoid) [18].

The deformity was classified as mild, moderate and severe depending on the degrees of HVA and IMA [2]. A hallux valgus deformity was characterized by less than 20° and IMA of less than 11°. A moderate deformity was characterized by HVA of 20° to 40° and IMA of <16°. A severe deformity was defined as HVA of more than 40° with IMA of more than 16°. According to these criteria, 42 (87.5%) feet had moderate deformity, whereas the remaining 6 (12.5%) feet had severe deformity. The undercorrection of the deformity was defined as a final HVA of more than 16° [7, 17].

Operative technique

All surgical procedures were done using regional anesthesia. A pneumathic tourniquet was applied above the ankle joint. A straight longitudinal skin incision was done medial to the extensor hallucis longus tendon. The joint capsule of the first metatarsophalangeal joint was incised longitudinal from the base of the proximal phalanx to the neck of the first metatarsal and dissected from the metatarsal bunion. Care was taken not to dissect the skin from the capsule. No release of the transverse metatarsal ligament, adductor hallucis tendon and lateral joint capsule was done. The metatarsal osteotomy was similar to the procedure of Lindgren

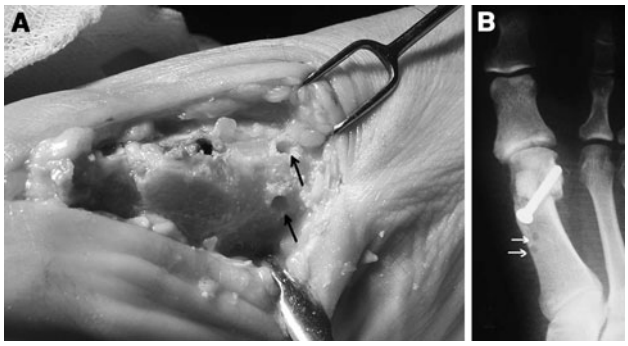

Fig. 1 **a** After distal metatarsal osteotomy and fixation with a lag screw, two holes (*black arrows*) are drilled into the proximal fragment for transosseous capsuloplasty. **b** The drill holes (*white arrows*) are seen on the anteroposterior radiograph

and Turan [13]. In addition, excision of medial bunion was done in the current study for all feet. After bunionectomy, a distal transverse metatarsal osteotomy was made at an approximately 30° angle from the longitudinal axis of the first metatarsal. The distal fragment was displaced laterally. The tip of the proximal fragment was resected when needed and the distal fragment was fixed with a 2.7-mm lag screw to the metatarsal shaft.

The capsuloplasty procedure was then performed for patients in Group A. Two holes were drilled into the proximal fragment in its metaphyseal region through one cortex in a dorsoplantar and mediolateral directions with the help of a drill guide (Fig. 1a, b). The first suture (2-0 Vicryl) was passed from the proximal aspect of the capsule to the plane between the capsule and the skin and then back approximately 10-mm distally. The suture was reinserted about 5–10-mm proximally and back again. The plicated medial capsule was then sutured through the drill holes to the bone and tied while hallux was held in fully corrected position (Fig. 2a–c). Afterwards, the first metatarsophalangeal joint was dorsi and plantar flexed to verify that the capsule has not been tightened too much to cause limitation of motion or overcorrecting into varus position. The subcutaneous tissue and skin were closed in standard fashion.

Postoperative treatment

The postoperative treatment was identical in both the groups. All patients were received a forefoot bandage that was applied between the first and second toes (Fig. 3a). Patients were examined at weekly intervals for dressing changes. A custom-made plaster walking boot (Fig. 3b) was applied on the fifth postoperative day and patients were allowed full weightbearing as tolerated. At the sixth week postoperatively, patients allowed to wear daily shoes.

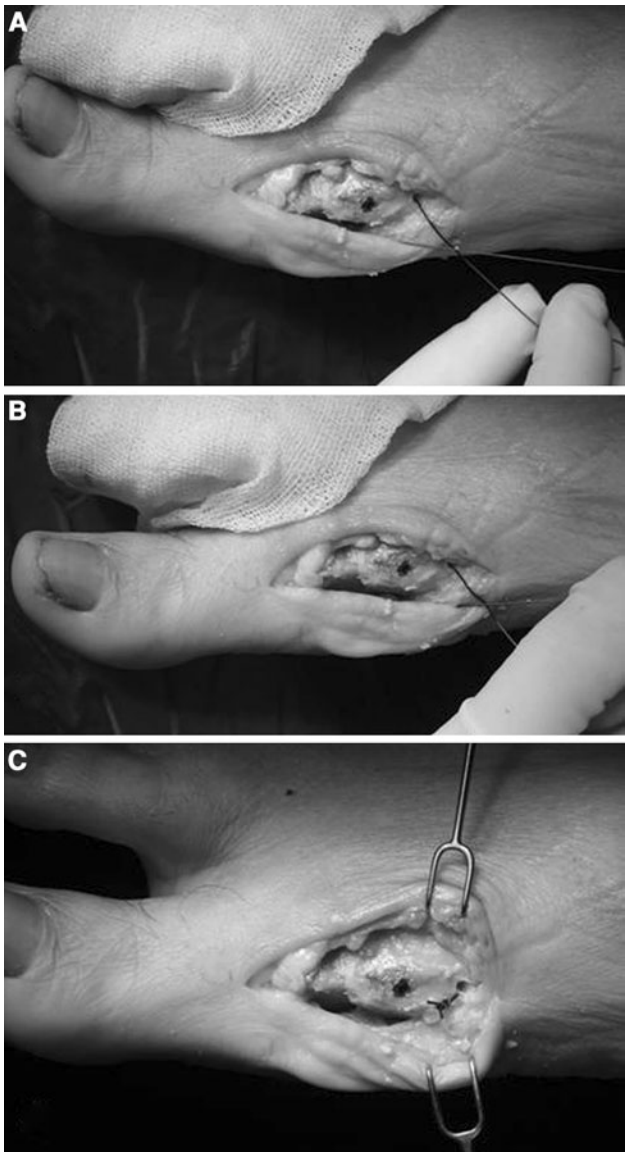

Fig. 2 The transosseous capsuloplasty technique (**a**). The plicated medial capsule is sutured through the drill holes to the bone (**b**, **c**). The suture is tied while the proximal phalanx is held in corrected position

Statistical analyses

The statistical analyses were performed using the NCSS 2007 program (NCSS Statistical Software, Kaysville, UT, USA). Descriptive statistics (mean and standard deviation) were computed. Unpaired *t* test and repeated one-way analysis of variance were used to compare the preoperative and postoperative data's within the groups. Unpaired *t* test also was used to compare the study data's between the groups. Categorical variables were compared with the χ^2 test. Mac Nemar's test was used to compare the reported measurements of qualitative data. The level of significance in the presented study was set at $P \leq 0.05$.

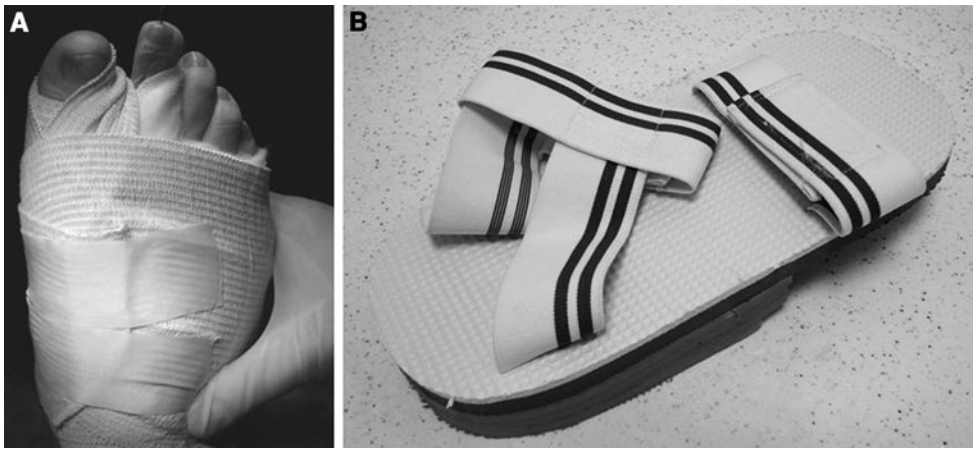

Fig. 3 **a** Forefoot bandage. **b** Custom-made plaster walking boot

Table 1 Baseline characteristics of patients included in this study

	Group A	Group B	*P* value
Number of patient	20	17	0.344
Number of feet	25	23	
Age at surgery (years)[a]	47.25 ± 12.63 (24–69)	51.12 ± 11.27 (26–68)	
Gender			
Male	1 (5%)	0 (0%)	0.350
Female	19 (95%)	17 (100%)	
Follow-up (months)[a]	12.96 ± 1.71 (12–22)	14.82 ± 5.15 (12–28)	0.120
Severity of the deformity[b]			
Mild	–	–	0.566
Moderate	22 (88%)	20 (87%)	
Severe	3 (12%)	3 (13%)	

[a] The values are given as the mean and standard deviation with the range in parenthesis

[b] The values are given as the number of the feet

Results

According to the baseline characteristics of the analyzed patients (Table 1), the difference between the two groups was not significant with regards to the age ($P = 0.344$) and gender ($P = 0.350$) of the patients, duration of the follow-up ($P = 0.120$) and severity of the deformity ($P = 0.566$).

Clinical results

At the final follow-up, both the groups improved significantly ($P = 0.0001$) in AOFAS scores. However, AOFAS scores in Group A were significantly greater than that in Group B ($P = 0.001$). Patients in Group A reported complete satisfaction in 22 (88%) feet and satisfaction with minor reservations in 3 (12%) feet. Patients with complete satisfaction or satisfaction with minor reservation in Group B were significantly lower than that in Group A. All three patients with severe hallux valgus deformity in Group B were dissatisfied regarding overall satisfaction and appearance of the foot (Table 2).

Radiological results

According to the preoperative, immediate postoperative and final follow-up values of the radiographic measurements (Table 3), the HVA, IMA and DMAA were significantly reduced ($P = 0.0001$) in both the groups. However, the decrease in IMA ($P = 0.041$) and DMAA ($P = 0.014$) was more apparent in Group A. Position of the medial sesamoid was significantly improved ($P = 0.0001$) in both groups with greater extent in Group A ($P = 0.023$). Only two (8%) feet in Group A had an HVA of 16°, whereas five (21.7%) feet in Group B had an HVA greater than 16° at the final follow-up.

Complications

In Group A, superficial wound infections occured in two (8%) feet that were successfully treated with oral antibiotics. One (4%) patient had an asymptomatic delayed union in this group at 6 months follow-up. It healed spontaneously before the final follow-up examination. The recurrence of the hallux valgus deformity occured in three (13%) feet in Group B. All

Table 2 Clinical outcomes of patients

	Group A	Group B	*P* value
AOFAS score[a]			
Preoperative	61.48 ± 9.37 (38–70)	61.74 ± 12.14 (31–78)	0.934
At the final follow-up	93.28 ± 3.67 (84–98)	84.35 ± 10.36 (61–97)	*0.001*
Overall satisfaction[b]			
Satisfied	22 (88%)	13 (57%)	*0.021*
Satisfied with reservation	3 (12%)	8 (34.4%)	
Dissatisfied	–	2 (8.6%)	
Cosmesis[b]			
Satisfied	19 (76%)	10 (43.5%)	*0.036*
Satisfied with reservation	6 (24%)	10 (43.5%)	
Dissatisfied	–	3 (13%)	

The italic values show the level of significance for *P* values ($P < 0.005$)

[a] The values are given as the mean and standard deviation with the range in parenthesis

[b] The values are given as the number of the feet

Table 3 Radiological outcomes of patients

	Group A	Group B	*P* value
Hallux valgus angle (°)[a]			
Preoperative	31.88 ± 6.21(20–40)	30.52 ± 5.77 (20–40)	0.438
Immediate postoperative	4.12 ± 3.83 (2–12)	4.57 ± 3.38 (0–10)	0.673
At the final follow-up	11.16 ± 2.75 (6–16)	12.61 ± 3.27 (8–20)	0.103
Intermetatarsal angle (°)[a]			
Preoperative	13.32 ± 3.21 (11–22)	14.65 ± 4.32 (12–25)	0.229
Immediate postoperative	8.08 ± 2.33 (2–12)	8.74 ± 2.77 (4–14)	0.375
At the final follow-up	8.4 ± 2.43 (4–13)	10.04 ± 2.98 (5–15)	*0.041*
Distal metatarsal articular angle (°)[a]			
Preoperative	15.72 ± 6.93 (9–20)	15.17 ± 3.97 (9–20)	0.742
Immediate postoperative	5.48 ± 3.62 (0–14)	5.91 ± 3.37 (0–12)	0.671
At the final follow-up	4.68 ± 2.53 (0–9)	7 ± 3.68 (0–12)	*0.014*
Sesamoid position[b]			
Preoperative			
Grade 0	–	–	0.396
Grade 1	10 (40%)	13 (56.5%)	
Grade 2	12 (48%)	8 (34.8%)	
Grade 3	3 (12%)	2 (8.7%)	
Sesamoid position[b]			
At the final follow-up			
Grade 0	13 (52%)	4 (17.4%)	*0.023*
Grade 1	5 (20%)	12 (52.2%)	
Grade 2	7 (28%)	7 (30.4%)	
Grade 3	–	–	

The italic values show the level of significance for *P* values ($P < 0.005$)

[a] The values are given as the mean and standard deviation with the range in parenthesis

[b] The values are given as the number of the feet

of them had severe hallux valgus deformity with the final HVA more than 16°. There was no evidence of hallux varus, nonunion or osteonecrosis in either of the groups.

Discussion

Capsuloplasty through the plication of the medial capsule is a part of the operation in many [5, 6, 11, 15, 17], although not all, published procedures in hallux valgus deformity. In the original description of Lindgren–Turan procedure [13], a medial capsulotomy was not performed. To the best of our knowledge, this is the first study to compare the results of Lindgren–Turan osteotomy and the same procedure combined with transosseous capsuloplasty in patients with moderate to severe hallux valgus deformity.

There are several limitations to this study. The first limitation is the relatively less number of patients. However, the

current study had good comparability in the baseline characteristics between the groups. The number of patients with severe deformity is also less. Both groups include three severe hallux feet. Therefore, we could not compare the results of severe deformities between the groups statistically. However, no recurrences of the deformity have occured in Group A, while three (13%) feet in Group B with severe hallux valgus deformity had a final HVA greater than 16°. The second limitation is the relative short duration of follow-up. Therefore, we conclude that both procedures used in the current study produce good short-term radiographic and clinical results in patients with moderate hallux valgus deformities. In addition, better clinical and radiographical measures were achieved with transosseous capsuloplasty in moderate and severe hallux valgus deformities.

Although some authors [1, 9, 16] reported good results in patients with higher HVAs and IMAs after treatment with distal procedures, there is a general agreement in the literature that the distal metatarsal osteotomy can be used for cases with an HVA up to 30° and IMA up to 15°, and no remarkable arthrosis in the first metatarsophalangeal joint for adequate correction of the deformity [2, 17]. In the original study [13], seven (16.6%) of 42 patients operated by Lindgren–Turan procedure had persisting HVA of greater than 15°. In another study [17] which compared the results of two different distal procedures, no significant differences in clinical improvement were seen between the Lindgren–Turan and the distal Chevron procedures, although a better radiographic correction was obtained with the Lindgren–Turan method. However 30% of 50 feet operated by Lindgren–Turan osteotomy showed undercorrection in this study. It was stated that the loss of correction was caused by extending the indications to more severe deformities. Thus, authors recommended combining the osteotomies in such patients with soft tissue surgery including plication of medial capsule to the soft tissue on the shaft of the metatarsal when the HVA was greater than 30°.

In the present study, 13 (52%) feet in Group A and 9 (39%) feet in Group B had an HVA greater than 30° and an IMA greater than 15° preoperatively. The undercorrection of the deformity is defined as a final HVA of more than 16° in the literature [7, 17]. According to this criteria, only two (8%) feet in Group A had an HVA of 16°, whereas five (21.7%) feet in Group B had an HVA greater than 16° at the final follow-up.

The importance of the medial capsule in hallux valgus deformity was evaluated in a cadaver study [12]. It was concluded that the medial capsule was an important element in stabilizing the first metatarsophalangeal joint and suggested that operative correction should include medial capsular repair. Medial capsular repair can be done by plication of medial capsule to the bone which can be termed as transosseous capsuloplasty. This technique similar to that used in the present study was reported in many previous studies and successful results were achieved in Mitchell osteotomy [8], proximal metatarsal osteotomy combined with distal soft tissue procedure [15] and scarf osteotomy [11]. In another study [6], it was reported that the anchor-enhanced capsulorrhaphy plays a significant role in maintaining the surgical correction in both the distal and proximal osteotomies.

The chosen operative technique must correct all elements of the hallux valgus deformity including prominence of the medial eminence, increased HVA and IMA, congruency of the metatarsophalangeal joint, pronation of the great toe and subluxation of the sesamoids [2]. The reduction of the sesamoids is an important issue in the treatment of hallux valgus deformity [2, 4]. An operation that does not reduce this subluxation by relocation of the first metatarsal head to a normal articulation with both the medial and the lateral sesamoid creates a risk for recurrent deformity [2]. Position of the medial sesamoid was significantly improved ($P = 0.0001$) in both the groups with greater extent in Group A ($P = 0.023$) in the present study. However, complete reduction of medial sesamoid was achieved in 52% of patients in Group A, whereas 17.4% of patients in Group B had complete reduction. This might be attributable to the possibility that transosseous capsuloplasty allowed to protect greater correction of the deformity with the advantage of holding the proximal phalanx in correct alignment and repositioning of the sesamoids.

Lindgren–Turan osteotomy combined with transosseous capsuloplasty yielded acceptable radiological and clinical outcomes. We conclude that this procedure is a preferable method in the surgical treatment of patients with moderate and severe hallux valgus deformities.

Acknowledgments The authors thank the patients who participated in this study and Rana Konyalıoğlu (statistician) for contributing to the statistical analysis.

References

1. Corless JR (1976) A modification of the Mitchell procedure. J Bone Joint Surg [Am] 58:138
2. Coughlin MJ (1996) Hallux valgus. J Bone Joint Surg [Am] 78:932–966
3. Easley ME, Trnka HJ (2007) Current concept review: hallux valgus part II: operative treatment. Foot Ankle Int 28:748–758
4. Esemenli T, Yıldırım Y, Bezer M (2003) Lateral shifting of the first metatarsal head in hallux valgus surgery: effect on sesamoid reduction. Foot Ankle Int 24:922–926
5. Goldfarb WL, Melillo TV, Levinson FN, Newman LM, Battey M (1980) The tear-drop capsulectomy and capsulorrhaphy: a new approach in aiding the soft tissue repair of hallux abductovalgus. J Foot Surg 19:199–201
6. Gould JS, Ali S, Fowler R, Fleising GS (2003) Anchor enhanced capsulorrhaphy in bunionectomies using an L-shaped capsulotomy. Foot Ankle Int 24:61–66

7. Hardy RH, Clapham JC (1951) Observations on hallux valgus; based on a controlled series. J Bone Joint Surg [Br] 33:376–391
8. Jehanzeb T, Dosani A, Mann CF, Faraj AA (2005) Clinical tip: transosseous capsular stabilization of modified Mitchell osteotomy. Foot Ankle Int 26:664–666
9. Johnson KA, Cofield RH, Morrey BF (1979) Chevron osteotomy for hallux valgus. Clin Orthop Relat Res 142:44–47
10. Kitaoka HB, Alexander IJ, Adelaar RS, Nunley JA, Myerson MS, Sanders M (1994) Clinical rating systems for the ankle-hindfoot, midfoot, hallux and lesser toes. Foot Ankle Int 15:349–353
11. Kristen KH, Berger C, Stelzig S, Thalhammer E, Posch M, Engel A (2002) The SCARF osteotomy for the correction of hallux valgus deformities. Foot Ankle Int 23:221–229
12. Kura H, Luo ZP, Kitaoka HB, An KN (1998) Role of medial capsule and transverse metatarsal ligament in hallux valgus deformity. Clin Orthop Relat Res 354:235–240
13. Lindgren U, Turan I (1983) A new operation for hallux valgus. Clin Orthop Relat Res 175:179–183
14. Mann RA, Coughlin MJ (1999) Adult hallux valgus. In: Mann RA, Coughlin MJ (eds) Surgery of the foot and ankle, 7th edn. C. V. Mosby, St. Louis, pp 159–269
15. Okuda R, Kinoshita M, Morikawa J, Jotoku T, Abe M (2000) Distal soft tissue procedure and proximal metatarsal osteotomy in hallux valgus. Clin Orthop Relat Res 379:209–217
16. Rossi WR, Ferreira JC (1992) Chevron osteotomy for hallux valgus. Foot Ankle 13:378–381
17. Saro C, Andrén B, Wildemyr Z, Felländer-Tsai L (2007) Outcome after distal metatarsal osteotomy for hallux valgus: a prospective randomized controlled trial of two methods. Foot Ankle Int 28:778–787
18. Smith RW, Reynolds JC, Stewart MJ (1984) Hallux valgus assessment: report of research committee of American Orthopaedic Foot and Ankle Society. Foot Ankle 5:92–103