CLINICAL ORTHOPAEDICS AND RELATED RESEARCH
Number 464, pp. 238–241

SECTION III
REGULAR AND SPECIAL FEATURES

CASE REPORT

Juvenile Dermatomyositis with Bilateral Progressive Knee Flexion Contracture

Melih Guven, MD; Purushottam A. Gholve, MD, MBMS, MRCS†; Arkady Blyakher, MD†; and Roger F. Widmann, MD†*

Juvenile dermatomyositis is a multisystem, inflammatory vasculopathy that primarily affects muscles and skin. Calcinosis is one of the most debilitating complications affecting patients with juvenile dermatomyositis. Calcifications resulting from calcinosis frequently are located on the elbows, knees, and other joints and can cause considerable disability with severe pain, joint contractures, skin ulcers, and muscle atrophy. Many therapies for calcinosis have been reported including diltiazem, probenecid, and alendronate. We report a patient surgically treated for bilateral knee flexion contractures with the Ilizarov technique. At 2.5 years' followup, the patient had full extension of both knees with 0° to 50° flexion and was walking independently. The Ilizarov technique provides an important option for correcting knee flexion contractures secondary to calcinosis in juvenile dermatomyositis.

Received: January 6, 2007
Revised: May 8, 2007
Accepted: May 24, 2007
From the *Goztepe Education and Training Hospital, 2nd Orthopaedic and Traumatology Clinic, Goztepe, Istanbul, Turkey; and the †Division of Pediatric Orthopaedic Surgery, Hospital for Special Surgery, New York, NY.
Each author certifies that he or she has no commercial associations (eg, consultancies, stock ownership, equity interest, patent/licensing arrangements, etc) that might pose a conflict of interest in connection with the submitted article.
Each author certifies that his or her institution has approved the reporting of this case report and that all investigations were conducted in conformity with ethical principles of research.
Correspondence to: Roger F. Widmann, MD, Associate Professor of Orthopaedic Surgery, Division of Pediatric Orthopaedic Surgery, Hospital for Special Surgery, 535 East 70th Street, New York, NY 10021. Phone: 212-606-1325; Fax: 212-717-0673; E-mail: widmannr@hss.edu.
DOI: 10.1097/BLO.0b013e3181257119

Juvenile dermatomyositis (JDM) is a multisystem, inflammatory vasculopathy that primarily affects muscles and skin.[1] It is a rare disease with a reported incidence of approximately three cases per million children.[7] Clinically detectable calcification occurs in 30% to 70% of children diagnosed with JDM and can cause substantial disability in the form of joint contractures, skin ulcers, and muscle atrophy.[8] Some patients with calcinosis have restricted joint motion and inability to walk because of joint contractures. We present a patient who was surgically treated for bilateral knee flexion contractures secondary to calcinosis caused by JDM.

Case Report

A 15-year-old boy with a long-standing history of JDM and bilateral knee flexion contractures of approximately 3 years' duration was referred to our clinic with progressive inability to walk over 3 years. He was diagnosed in 1990, at age 3, with JDM. His past medical treatment included steroids and methotrexate. He did not have any previous surgery. He was unable to stand or bear weight on his lower extremity secondary to severe bilateral knee flexion contracture. He was wheelchair-bound.

Physical examination revealed prominent subcutaneous calcifications over the lateral aspect of his distal humerus

Fig 1. A lateral photograph shows 90° flexion contractures of both knees.

and olecranon and in the popliteal fossa along the hamstring tendons. He had bilateral hip flexion contractures of 25° and hip range of motion was measured from 25° to 80° flexion bilaterally. Both knees had flexion contractures of 90° with further range of motion from 90° to 140° (Fig 1). His ankle dorsiflexion was 15° bilaterally with plantar flexion of 40°. He also had shoulder and elbow contractures. His neurovascular examination was normal.

Radiographic examination of the knees revealed extensive calcification in the soft tissues posterior to the femurs with 90° flexion contractures of both knees (Fig 2A–B). He also had major subcutaneous calcifications on all images, including his hips and upper extremities (Fig 2C). MRI showed calcification and fibrous thickening of the hamstring tendons.

Surgical correction of the flexion contractures of the knees with an Ilizarov fixator was planned to improve walking and transfers. Physical therapy was recommended to stretch the hip flexion contractures.

Surgery was performed under spinal-epidural anesthesia. The medial hamstrings were percutaneously lengthened and the biceps femoris muscle was fractionally lengthened using an open approach. A preconstructed Ilizarov fixator was mounted on the tibia and femur (Fig 3). The femoral construct had two full rings and one proximal arch. The tibial construct was comprised of two full rings. The center of rotation of the knee was marked with a Kirschner (K) wire. Hollister et al[5] reported the center of rotation of the knee in the flexion-extension axis is closely located at the intersection of a line drawn along the posterior cortex of the femur and another line drawn along the distal growth plate on a true lateral radiograph of the knee. We used these landmarks to mark the center of rotation of the knee. The femoral and tibial components were connected by medial and lateral hinges, which were placed slightly anterior and proximal to the axis of rotation of the knee to achieve slight distraction of the articular surfaces as correction of the flexion deformity was performed. The rings were secured to the femur and tibia with K wires and half pins. Posteriorly a motor rod was attached between the tibial and femoral components for distraction. We did not obtain any acute correction after the hamstring release

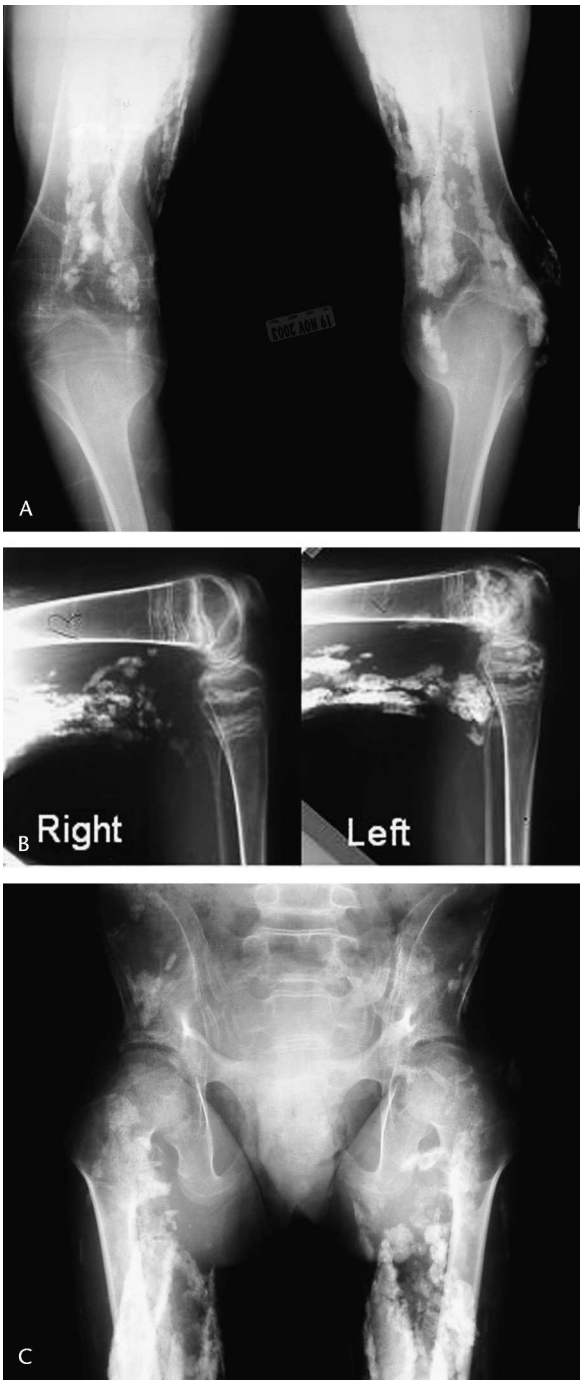

Fig 2A–C. (A) An anteroposterior radiograph of both knees, (B) lateral radiographs (in maximum extension) of both knees, and (C) an anteroposterior radiograph of the pelvis reveal severe calcifications.

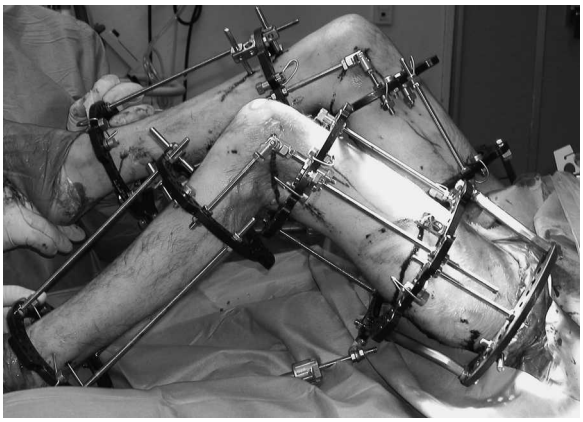

Fig 3. An Ilizarov ring fixator with hinge was applied to the tibia and femur of each leg.

and application of the Ilizarov fixator. The tendon and muscles were stiff and calcified, thus inhibiting any acute correction. Our customary practice is to commence contracture correction immediately after Ilizarov surgery. However, in this particular case, we wanted the surgical skin incision to heal before we commenced distraction. Hence, the distraction of the motor rod was started after 1 week at a rate of 3 mm per day. The distraction rate was changed temporarily from 3 to 1 mm per day for the right knee when the patient experienced mild sensory changes over the dorsum of his foot. Otherwise, the patient tolerated the gradual correction well. He did not have posterior knee subluxation develop (Fig 4A). There were no other complications. He had full extension in both knees 5 months after the index surgery. Active and passive knee range of motion exercises were started three times a day. The motor rod was removed temporarily during the knee exercises and reapplied immediately after exercises to maintain extension positioning of the knee. The Ilizarov fixators were removed 6 months after the index surgery.

On removal of the fixators, the patient was placed in a knee-ankle-foot orthosis with a drop lock knee joint to prevent further contracture. He then was able to walk with minimal assistance either using a walker or holding someone's hand. Between the first and second years postoperatively, he continued to use a nighttime knee extension splint. At the final followup (2.5 years postoperatively), he had full passive extension and 50° flexion of both knees and was able to walk independently (Fig 4B).

DISCUSSION

Calcinosis is one of the most debilitating complications affecting patients with JDM. It is associated with severe or inadequately treated JDM.[10] Calcifications resulting from calcinosis frequently are located on the elbows, knees, and other joints and they can cause substantial disability with severe pain, joint contractures, skin ulcers, and muscle atrophy.[10] Numerous therapies for calcinosis have been reported, including diltiazem, probenecid, and alendronate.[8] Occasionally, calcinosis may undergo spontaneous partial resolution over time.[8] In cases with long-standing calcinosis, calcifications are not responsive to medical treatment and produce major joint contractures.

Knee flexion contractures have been treated with gradual correction by using external fixation devices in conditions such as arthrogryposis, multiple pterygium syndrome, spina bifida, juvenile rheumatoid arthritis, hemophilia, pyarthrosis, diastrophic dwarfism, polio, trauma, and burn injuries.[2–4,6,9] Volkov and Oganesian[9] reported encour-

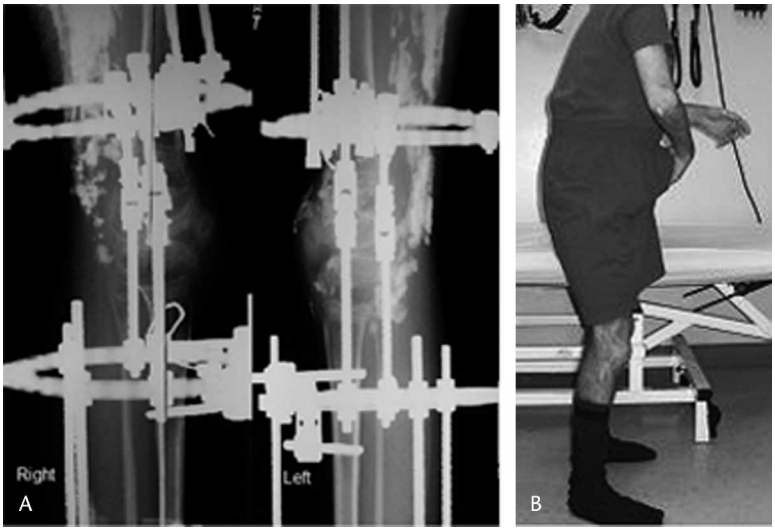

Fig 4A–B. (A) There is no evidence of posterior subluxation of the knees on lateral radiographs. (B) Two and a half years postoperatively, the patient had full extension of both knees and was able to walk independently.

aging results after correcting 31 knee contractures using a hinge-distractor apparatus. Their apparatus worked well for extension and flexion contractures of the knee.

Severe knee flexion contracture can be disabling, causing decreased mobility and functional leg-length discrepancy. In JDM, other joints also may be involved, as in our patient. Multiple joint involvement decreases the quality of life. Contractures in the lower extremities may limit the ability to walk. The treatment modalities for knee contracture include serial casting, osteotomies, soft tissue procedures, and gradual joint distraction with external fixators.[2,4] Supracondylar extension femoral osteotomies create a secondary deformity to correct the primary deformity and may lead to abnormal joint-loading forces in the ambulatory patient.[4] Soft tissue releases often are not sufficient to gain full correction and the traditional method of serial casting can be complicated by skin necrosis, joint cartilage compression, and joint subluxation.[2,4] The Ilizarov method can be helpful in correcting severe fixed flexion deformity of the knee with relatively few complications. There can be some residual stiffness and overall decrease in the total arc of motion of the knee after correction of the contracture with Ilizarov fixator.[4] However, this may be an acceptable price to pay for repositioning the knee in a more functional position. Special attention is necessary to prevent posterior subluxation of the knee and vascular or neural injury.[2] Placing the hinge anterior to the center of the rotation of the knee distracts the joint and placing it proximal to the rotation of the knee causes anterior translation of the tibia, thus counteracting the tendency for the tibia to subluxate posteriorly. Careful preoperative planning and close followup, including structured physical therapy, is essential for optimal results.

The Ilizarov technique provides an important treatment option for correcting knee flexion contractures secondary to calcinosis in JDM.

References

1. Cassidy JT, Petty RE. Juvenile dermatomyositis. In: Cassidy JT, Petty RE, eds. *Textbook of Pediatric Rheumatology*. 4th ed. London, UK: WB Saunders; 2001.
2. Damsin JP, Ghanem I. Treatment of severe flexion deformity of the knee in children and adolescents using the Ilizarov technique. *J Bone Joint Surg Br*. 1996;78:140–144.
3. Gillen JA, Walker JL, Burgess RC, Stevens DB. Use of Ilizarov external fixator to treat joint pterygia. *J Pediatr Orthop*. 1996;16: 430–437.
4. Herzenberg JE, Davis JR, Paley D, Bhave A. Mechanical distraction for treatment of severe flexion contractures. *Clin Orthop Relat Res*. 1994;301:80–88.
5. Hollister AM, Jatana S, Singh AK, Sullivan WW, Lupichuk AG. The axes of rotation of the knee. *Clin Orthop Relat Res*. 1993;290: 259–268.
6. McCready DA, Colyn HJ. Soft tissue distraction and correction of the knee contracture using the Ilizarov frame. *J Bone Joint Surg Br*. 2005;87(suppl III):273.
7. Mendez EP, Lipton R, Ramsey-Goldman R, Roettcher P, Bowyer S, Dyer A, Pachman LM. NIAMS Juvenile DM Registry Physician Referral Group. US incidence of juvenile dermatomyositis, 1995–1998: results from the National Institute of Arthritis and Musculoskeletal and Skin Diseases Registry. *Arthritis Rheum*. 2003;49: 300–305.
8. Ramanan AV, Feldman BM. Clinical outcomes in juvenile dermatomyositis. *Curr Opin Rheumatol*. 2002;14:658–662.
9. Volkov MV, Oganesian OV. Restoration of function in the knee and elbow with a hinge-distractor apparatus. *J Bone Joint Surg Am*. 1975;57:591–600.
10. Yun SJ, Lee JB, Kim SJ, Lee SC, Won YH, Kand HC. Calcinosis cutis universalis with joint contractures complicating juvenile dermatomyositis. *Dermatology*. 2006;212:401–403.